

Veterinary Specialists & Animal Emergency Service

Winter 2011 Newsletter



Holiday Pet Dangers
Page 1 & 4



Radiology Corner
Page 2



Success Story: Dilinja
Page 3



News & Updates from VSES

VSES WEBSITE UPDATES

We now have numerous resources available on our website! Visit veterinaryspecialistsofrochester.com and click Referring Veterinarians at the top of the site to view:

- VSES newsletters dating back to 2009
- An instruction sheet for PACS navigation. You now have access to all imaging studies and reports for your patients online.
- A copy of our most up-to-date referral form for printing. You can also submit referrals online by creating a referring veterinarian account.
- A link to provide VSES with feedback on our website. You can access directly at www.surveymonkey.com/VSESDVM.

We are on Facebook! To "like" our page, log in to Facebook and search for Veterinary Specialists of Rochester.

CONGRATULATIONS ON RECENT PUBLICATIONS

Drs. May and Mehler are contributors in 2011 text book *"Veterinary Clinics of North America. Small Animal Practice. Surgical Complications"* edited by Dr. Chris Adin. They kindly donated a copy, which is available in the VSES

conference room.

VSES ON CHANNEL 13

Channel 13WHAM News featured VSES surgeons on Oct. 21 after they performed a life-saving surgery on Oct. 19 for shelter dog Frenchy, who recovered and was recently adopted. Watch the video clip by visiting www.13wham.com and searching for Frenchy or by clicking the link on the Facebook page for Veterinary Specialists of Rochester.

DERMATOLOGY UPDATE

Dr. Vogel has accepted a full-time position with a clinic in New England. He completed his last day with VSES in November. Please join us in wishing him the best! If you have any questions about care for your patients, please do not hesitate to contact us at (585) 424-1277.

VSES HOSTS WINTER BAZAAR FOR MVA HOPE

On Saturday, Dec. 10, VSES will host Hope's Winter Bazaar at the Brighton Town Park Lodge. Proceeds from the sale of craft/bazaar items will benefit the MVA Hope Foundation. Visit mvahopefoundation.org and click on Events for updated information.

Holiday Pet Hazards: What's dangerous for pets this time of year?

**By Kristen Woosley,
DVM, DACVECC**

The holidays bring plenty of festivities, but certain fundamentals of the season can be dangerous for pets. This article outlines common holiday hazards and how they affect pets.

PLANT: Poinsettia

Though traditionally thought of as quite toxic to animals, the potential for poinsettia poisoning is overhyped. Exposure to poinsettias' milky, detergent-like sap may irritate the skin and mouth and may cause vomiting and diarrhea, but serious or fatal poisoning is highly unlikely.

PLANT: Mistletoe

American mistletoe is often used in the U.S. as a Christmas decoration and

is less toxic than its European counterpart. Ingesting American mistletoe commonly causes self-limiting vomiting and mild neurological depression, but this plant and others in the mistletoe family have the potential to cause more serious problems, such as low blood pressure and cardiovascular collapse resulting from the plant's toxic characteristics.

PLANT: Holly

The most likely problem caused by ingesting holly is irritation to the gastrointestinal tract from the saponins (similar to poinsettias) and physical damage to the stomach and intestinal tract from the spiny points of the leaves. Though holly also contains methylxanthines (also found in

chocolate and caffeine) and cyanogens, these chemicals rarely lead to poisoning from small ingestions of the plant. Additionally, large ingestions of holly may cause a bowel obstruction because the leaves are difficult to digest.

BAKED GOODS: Chocolate

We've all heard that chocolate can be toxic to pets, but how much is too much? Chocolate and cocoa contain theobromine, a chemical similar to caffeine that's highly toxic to dogs and cats. The darker or more concentrated the chocolate, the more theobromine it contains. Therefore, baker's chocolate, semi-sweet chocolate, and gourmet dark chocolates are most dangerous.

Continued on page 4

Veterinary Specialists & Emergency Service

825 White Spruce Blvd
Rochester, N.Y. 14623
(585) 424-1277

CARDIOLOGY

Anna Gelzer, DMV,
DACVIM (Cardiology)

CRITICAL CARE

Kristen Woosley, DVM,
DACVECC

EMERGENCY

Sarah Brawdy, DVM
Kimberly Dodge, DVM
Simon Kirk, DVM,
Hospital Co-Director
Johnny Lamb, DVM
Thomas Linnenbrink, DVM
Joseph Wilder, DVM, DABVP

INTERNAL MEDICINE

Michael Koch, VMD,
DACVIM
*Consultant: Veterinary Laboratory
of Rochester*

OPHTHALMOLOGY

Kent Burgesser, PhD, DVM,
MS, DACVO,
Hospital Co-Director

RADIOLOGY

Jennifer Bouma, VMD,
DACVR

SURGERY

Justin Greco, DVM, DACVS
Lauren May, VMD, DACVS
Stephen Mehler, DVM,
DACVS

CONSULTING SERVICES

Neurology
*Curtis Dewey, DVM, DACVIM
(Neurology), DACVS*

Outpatient Ultrasound
Meg Thompson, DVM, DACVR



RADIOLOGY CORNER: PACS Facts

By Jennifer L. Bouma, VMD,
Diplomate of the American College of Veterinary Radiology

DID YOU KNOW?

PACS stands for **P**icture **A**rchiving and **C**ommunication **S**ystem.
DICOM stands for **D**igital **I**maging and **C**ommunications in **M**edicine.

DICOM is a universal information technology standard developed in 1993. The purpose of developing the DICOM standard was to ensure the compatibility of digital radiology images regardless of vendor/manufacturer.

DICOM compatibility of digital radiology images includes computed radiography, digital radiography, ultrasound, echocardiography, MR, CT, digital fluoroscopy and dental radiography.

Maintaining DICOM format of images ensures easy viewing and manipulation of images with *DICOM viewers*. Unfortunately, not all vendors comply with DICOM standards, and DICOM format **is not** maintained when images are saved as jpeg and sent through **email**. *This is why we ask that radiograph images are not sent via email for referrals at VSES.*

DID YOU KNOW?

You have access to all imaging studies and reports for your patients who are seen through the Veterinary Specialists and Animal Emergency Service. This is not just for hospitals with CR (computed radiography) in their practices, but for **all** referring hospitals. You are able to view all diagnostics, including radiographs, ultrasound, echocardiography and MRI.

DID YOU KNOW?

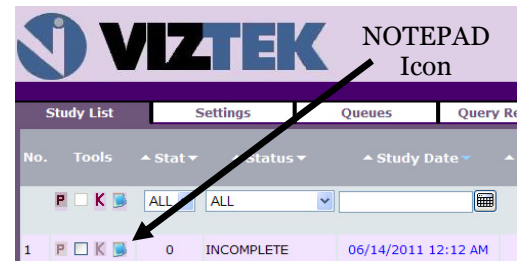
Access to the images are provided via web interface. If you have never logged on OR if you forgot your password/username, please call and ask to speak with the radiology technician on duty. The radiology department at VSES is available seven days a week to help you with PACS questions and can be reached at (585) 424-1260 or (585)424-1277

VIEWING RADIOGRAPHS AND RADIOGRAPH REPORTS THROUGH WEB PORTAL FOR PACS IMAGES

- Log in to your account via the web interface.
- First, single click on the row with your patient's information so it is highlighted blue.
- Once it is blue, double click to bring up the images.

REPORTS

- At the left side of the row there are a couple of icons, including a notepad icon that will either be blue or gray.
- If the notepad is blue, single left click on the icon will pull up the 'study notes'.
- If the doctor requested a radiograph consult (Dr. Bouma, Dr. Thompson or PetRays) it will be entered here.
- If you would like to print the report for your medical record, press the print tab at the bottom of the notes window.



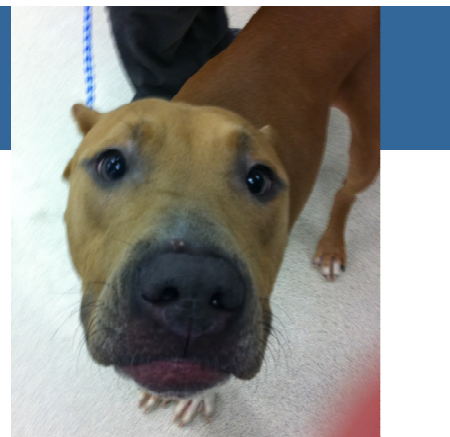WHAT IF YOU DO NOT SEE YOUR PATIENT LISTED?

When you log in to your account, if your patient's name doesn't appear in the list on the first screen, make sure to check the box at the bottom of the page for full scan. Then you can search for your patient by entering either patient name or last name on the blank line at the top of the list, below the 'patient name' tab and press enter. If the patient does not appear after full scan search, there may be difference or error in the spelling of the patient name or last name.

If you still do not see your patient's name, please call VSES and ask to speak to a radiology technician, the radiology coordinator or Dr. Bouma. We may need to adjust the referring information that is entered in the PACS.

Success Story: Dilinja

By Lauren May, VMD, DACVS



Dilinja, a 2-year-old Dogo Argentino mix, presented to Animal Emergency Service for suspected gastrointestinal obstruction (blockage of the intestine or stomach, so nothing can pass).

Dilinja's primary veterinarian in Hershey, Penn., saw him for lethargy, decreased appetite and vomiting three days before he came to Animal Emergency Service. Important pertinent history at that time included Dilinja possibly had eaten CD cases two days before. His vet took radiographs at that time, but nothing out of the ordinary was found, so Dilinja was discharged to the owner for monitoring over the weekend. He continued to vomit and returned to his primary veterinarian for re-evaluation. Blood work performed at that time showed decreased platelets and multiple decreased electrolytes.

Dilinja was then referred to the Animal Emergency Service, which the owner opted to pursue, and he was transferred there later that evening.

Emergency service staff noted Dilinja to have painful abdominal palpation. Abdominal radiographs revealed a pyloric outflow obstruction (blockage of the stomach) with plication (bunching) of the small intestines. Plication of the intestines is consistent with the diagnosis of a linear foreign body. Common linear foreign bodies in small animals include string, carpet and cloth. Linear foreign bodies often get anchored in the stomach or around the tongue (more common in cats) and the rest of the foreign body moves into the intestines, causing it to bunch up on itself and leading to damage

of the intestinal wall. Therefore, in an effort to minimize damage to the intestines by the foreign material, surgery was recommended once the patient had been stabilized.

Dilinja went into surgery around 5 a.m. At surgery, free abdominal fluid was noted in the abdomen (which is abnormal) and foreign material was noted to extend from the stomach through a large amount of the small intestine. On thorough evaluation of the intestine, approximately 1 foot of intestine was noted to be extremely unhealthy and two areas of perforation (holes) were noted in the intestine wall. Perforations in the intestinal wall allow the contents of the intestine to leak free into the abdomen and surround the organs in the abdominal cavity. The intestines normally contain not only the food and liquid that has been ingested, but also bacteria. When bacteria are free in the abdomen, as can occur with perforation of the intestine wall, the condition is termed septic peritonitis.

Septic peritonitis can occur for multiple reasons, including rupture of the urogenital tract (such as perforation of the uterus due to a uterine infection termed pyometra), penetrating abdominal wounds such as bite wounds or gun shot wounds, and rupture of the gastrointestinal tract. Rupture of the gastrointestinal tract is common, reported to be the cause of septic peritonitis in 60 percent of cases.

Septic peritonitis is an extremely life-threatening condition because it can lead to widespread inflammation and infection in the body. It requires emergency surgery and intense supportive care. Even when the patient is treated with emergency surgery and intense post-operative care, patients with septic peritonitis generally have a 43 percent mortality rate.

At surgery, the foreign body was removed and the unhealthy appearing intestine was resected. Before closing, a large amount of sterile fluid was flushed and suctioned from the abdomen to try to remove the intestinal contents that had leaked into the abdomen. Also, drains were placed that allowed fluid that was

produced in the abdomen postoperatively to be removed and monitored closely.

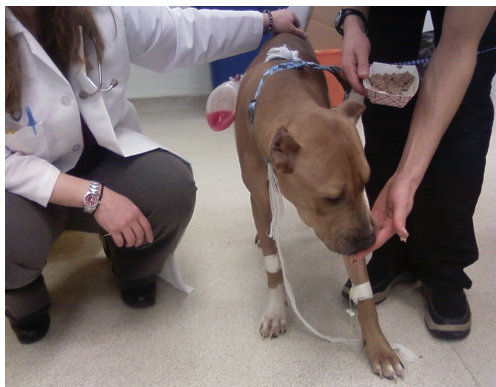Postoperatively, Dilinja was in critical condition. He had severe diarrhea and regurgitation and the main blood protein, albumin (which is extremely important for healing and keeping fluid in the blood vessel) dropped extremely low. He required intense supportive care, including fluid therapy, pain medications, antibiotics, regular blood work monitoring, blood pressure monitoring and gastrointestinal protectants.

He started eating a few bites of food three days after surgery and from there his appetite continued to improve. He was discharged to the owner at eight days postoperatively and headed back to his home in Pennsylvania, a five-hour drive!

Dilinja is doing well at home currently and has made a full recovery. He has lost the privilege to most toys except a KONG ball (to avoid another foreign body surgery!), but he is otherwise back to his normal everyday life.

Without the extreme dedication Dilinja's owner had to him, his primary veterinarian's attentiveness and the intense care he was able to receive, he would not have survived. His condition emphasizes the importance of the emergency service and the positive outcome that can occur with septic peritonitis in a patient who receives emergency surgery and intense postoperative critical care.

It is important to be aware of how something as simple as eating something they should not have can become life threatening to your pet. When your pet may face an obstruction of the gastrointestinal tract by foreign material, it is vital to diagnose as early as possible to give the best prognosis possible.



Lauren May, VMD, DACVS, earned her VMD degree from the University of Pennsylvania School of Veterinary Medicine and completed a rotating internship in small animal medicine and surgery at the University of Minnesota College of Veterinary Medicine. She began her residency at the University of California at Davis Veterinary Teaching Hospital before moving to Michigan State University's College of Veterinary Medicine, where she completed her residency. Dr. May performs orthopedic and soft tissue surgery and has a strong professional interest in surgical oncology and urogenital surgery.

Steve Mebler, DVM, Diplomate ACVS, assisted with this article. For more info, read his bio at vetspecialistsofrockchester.com/vet_mehler.php.

Veterinary Specialists & Emergency Service
825 White Spruce Blvd.
Rochester, NY, 14623
585-424-1277

Continued from page 1

Dark-chocolate-covered espresso beans are particularly problematic since they may contain large amounts of both theobromine and caffeine.

Milk chocolate contains lower amounts of theobromine. Typically, an animal needs to consume at least 1 to 2 ounces of milk chocolate per kilogram of body weight before symptoms occur.

The amount of chocolate in baked goods, including cookies, cakes and candies, is often relatively low and less frequently causes serious chocolate poisoning.

However, significant gastrointestinal upset, such as vomiting and diarrhea, are common following the ingestion of any chocolate product.

Signs of chocolate or theobromine poisoning include salivation, vomiting, diarrhea, hyperactivity, pacing, tachycardia (rapid heart rate), cardiac arrhythmias, tremors and seizures.

Ingestion of chocolate may also cause pancreatitis because of the high fat content. Obese dogs and those on certain medications (such as potassium bromide, azathioprine, etc.) are more at risk for pancreatitis.

BAKED GOODS: Bread Dough

During the process of rising, the yeast in bread dough produces significant amounts of ethanol, the active component of alcoholic beverages. A curious dog has been known to steal a loaf of rising bread while the unsuspecting owners are out holiday shopping or visiting. The warm temperature in the dog's stomach causes the dough to rise rapidly, releasing significant amounts of ethanol.

This may result in physical bloating and discomfort or, more seriously, respiratory depression, central nervous system depression, coma and death. If treated early, the prognosis for full recovery of bread dough ingestion is very good. However, many owners are not aware that this ingestion can be problematic and do not take them to the vet until evidence of toxicosis develops.

FOUND IN FOOD: Xylitol

Xylitol is a commonly used sugar substitute found most notoriously in sugarless gum, but it is also frequently used in sugar-free baked goods, candy and toothpaste. In humans the compound is completely harmless, but in dogs, it has very severe side effects including hypoglycemia (low blood sugar) and liver

failure. The underlying reason for the difference in human and canine response to the compound is not completely understood but is suspected to be a result of differences in the metabolism of the compound between the species.

Dogs may demonstrate clinical signs of hypoglycemia (weakness, staggering, seizures) as early as 30-60 minutes following ingestion followed by evidence of liver failure (vomiting, anorexia, jaundice) in as early as nine hours following ingestion.

Dogs treated before the onset of liver failure generally have a very good prognosis for full recovery. However, the prognosis is more guarded for dogs that develop fulminant liver failure. For this reason, it is important to seek veterinary attention as early as possible following known ingestion for the best possible outcome.

IMPORTANT PHONE NUMBERS

- **VSES:** 585-424-1277
- **ASPCA Poison Control Center:** 1-888-426-4435 or aspcapro.org/animal-poison-control.php
- **National Animal Poison Control Center:** 1-800-213-6688 or petpoisonhelpline.com