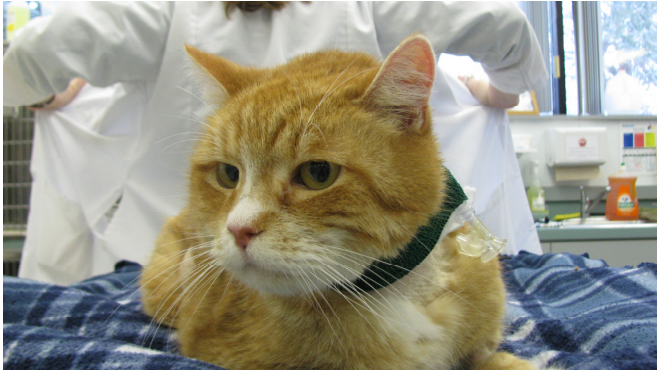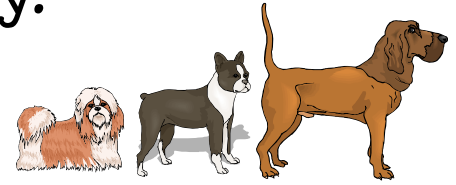
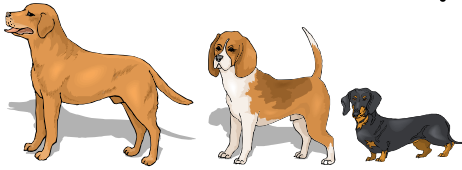


VSES Success Story:

“Leo”



Leo

Leo, an 11 year old male domestic shorthair cat, presented to VSES for decreased appetite, vomiting, and jaundice (yellow color to the skin, gums, and whites of the eyes). On physical examination, Leo was jaundice and his liver was enlarged. A serum biochemistry revealed high liver enzymes as well as bilirubin. Together these abnormalities suggest liver failure. Leo also had low potassium and phosphorus, electrolyte changes that can occasionally be seen with liver failure. On ultrasound, his liver was big and bright (hyperechoic) and the wall of the gall bladder and bile ducts were thickened. His pancreas

was enlarged and darker than usual (hypoechoic) and the tissue around it was bright. These ultrasound changes are consistent with a diagnosis of pancreatitis (inflammation of the pancreas) with concurrent cholangiohepatitis (inflammation of the gall bladder, bile ducts, and liver). Because the liver, gall bladder, and pancreas are so close to each other in cats, inflammation in one area often leads to inflammation of the others. This is likely what happened in Leo. Another cause of liver failure in cats is *Toxoplasma* infection. Leo's blood tests for this infection were negative. Since Leo had not been eating for awhile before coming into the hospital, he also likely had a condition call hepatic lipidosis, or “fatty liver”.

Hepatic lipidosis can occur any time a cat does not eat enough or absorb enough food to meet their nutritional needs. This nutritional deficiency can happen for a number of reasons including gastrointestinal disease, pancreatitis, liver disease, kidney disease, or even emotional reasons (Leo's owner was in the hospital which may have made him more stressed). No matter what the underlying cause of the “fatty liver” is, the condition can be quite serious and even life-threatening as it can cause the cat to develop severe liver failure.

“Fatty liver” can progress very quickly in cats. Therefore, it is important that owners always pay close attention to their cats' eating habits and notify their veterinarian if they notice a decreased appetite for more than two days. We generally recommend aggressive medical management for cats who are not eating normal for three or more days. The most important way to prevent or treat “fatty liver” is to get good nutrition into the cat. Sometimes, anti-nausea medication or appetite stimulants will be used. If there is an underlying cause for why the cat stopped eating, it needs to be addressed. Often owners will try to force feed their cats but it is very difficult to get sufficient amounts of food into them with force feeding and you can induce food aversions.

Often, in these patients, we recommend the placement of a feeding tube to help families be able to get nutrition into their cat while we address the underlying reason the cat is not eating on his or her own. Depending on the situation, different feeding tubes are used, but most commonly we use esophageal feeding tubes (into the esophagus). While most owners are nervous at first, it is easy to learn how to use these tubes at home. Prior to each feeding, we encourage the cat to eat on his or her own, but if they are not interested in eating, we can ensure that they get food through the tube. Esophageal tubes are for short terms use (weeks to months) and once the cat is eating well again, we can easily remove the tube. Overall, cats who are not eating well have a guarded prognosis, meaning that while some cats do not make it, a significant number of cats can recover from the condition. The most important factors in their prognosis are how quickly the problem is addressed (the sooner the better!); the cause of the decreased appetite and how quickly it can be dealt with; and how aggressively the decreased appetite is treated.

VSES Success Story Page 2:

“Leo”

At VSES, we consider cats with decreased appetites critical patients who should be dealt with on a fairly urgent basis.

Leo had an esophageal feeding tube placed, through which he was able to get food and medication in a non-stressful manner. Leo was given antibiotics to cover for bacteria causes of cholangiohepatitis, anti-inflammatory prednisone to decrease the inflammation associated with cholangiohepatitis, anti-nausea medications, an appetite stimulant, and potassium supplementation.

Once the tube was placed, he slowly started to improve. As soon as he was handling his feedings well and his electrolytes began to improve, he was sent home for further supportive care. He began eating more on his own and his liver values improved and then normalized. About three weeks after placing the tube, Leo's appetite was completely back to normal and he was off of the anti-nausea medications and appetite stimulant. We kept the feeding tube in for an extra week while he finished getting the rest of his medications; it was much easier to give him medications this way. Leo's feeding tube was removed about one month after its placement. He continues to do fabulous at home and his blood work changes have normalized.